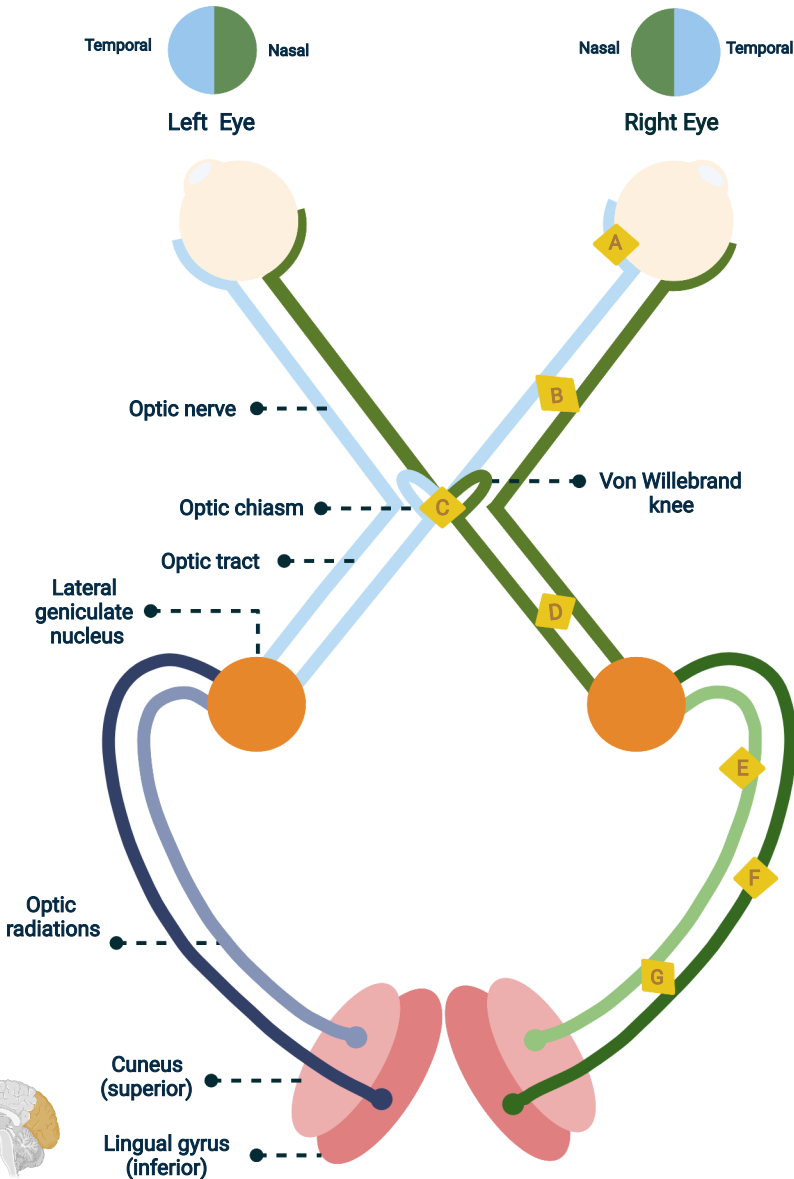


Visual Field Defects



		Most frequent pathologies	
		Central scotoma	Age related macular degeneration
		Total blindness	Stroke, Optic neuritis
		Bitemporal hemianopia	Pituitary adenoma
		Contralateral homonymous hemianopia	Neoplasm, MCA occlusion
		Inferior contralateral quadrantanopia	PCA occlusion
		Superior contralateral quadrantanopia	MCA occlusion
		Contralateral homonymous hemianopia with macular sparing	PCA occlusion
		Binasal hemianopia	Carotid artery aneurism
		Tunnel vision	Glaucoma
		Superior altitudinopia	Bilateral lingual gyrus destruction
		Inferior altitudinopia	Bilateral cuneus destruction