Clinical Case

González-Salido Jimena
Fuentes-Mercado Alfredo
Navarro-Sánchez Valeria
Pinta-Castro Alejandro

Patient Identification

→ **Type of interrogation:** direct and indirect

- Male
- 59 years old
- **Nationality** Mexican
- **Place of birth:** Poza Rica, Veracruz
- **Residence:** Ixtapaluca, State of Mexico
- **Marital status**: Married
- **Occupation:** Helps run vegetable stand

Family history

- Mother: died at age 45 due to unspecified heart disease
- Father: apparently healthy

Non-pathological personal history

- Smoking: denied
- Alcoholism: positive, mentions drinking a beer on Sundays

Pathological Personal History

- **HTN:** 24 years of evolution.
  - Amlodipine 5 mg
  - Losartan 50mg
- **Diabetes Mellitus:** 5 years of evolution, without adequate adherence to treatment and lack of follow-up to dietary recommendations
  - Glibenclamide 5 mg
  - Metformin 850 mg
- **Fractures of C1 and C2** at 22 years due to a car accident with surgical resolution (without sequelae)

Chief Complaint

14:00 hrs
Sudden onset of dizziness, tinnitus (right ear) and paresthesia on the right side of the head while crossing the street

16:30 hrs
He was admitted to the emergency room with a "drunk feeling" (dysarthria, dizziness), normal CT scan, and symptoms improve spontaneously. He was discharged with a request for MRI, atorvastatin 80 mg every 24 hours and aspirin 100 mg every 24 hours

18:30 hrs
When getting out of bed, he falls due to weakness of the right side of the body and diplopia

Wednesday, October 13, 2021

Thursday, October 14, 2021

Friday, October 15, 2021

He is taken to a private doctor. BP take results in 160/110 mmHg, so sublingual captopril 25 mg was administered, as well as diphenidol injected IM.
Stays stable for 10 minutes and suddenly gets worse, so he is transferred to a hospital.

13:00 hrs
His wife notices him with dysarthria but doesn't give it importance.

19:40 hrs
He is re-admitted to the ER

He continues to be in the emergency room, hemodynamically stable.

Physical examination

Somatometry:

- Size: 1.74cm
- Weight: 100kg
- BMI: 37.31 kg/m2

Vital signs

- 87 bpm
- BP: 147/73 mmHg
- FR: 23rpm
- SatO2: 96%

Overall physical examination:

- Loss of skin turgor in lower limbs
- Multiple abrasions on the anterior leg
- Thickened and yellowish nail color on both feet
- Rhythmic precord without murmurs
- Neck arteries difficult to auscultate due to thick neck at the expense of panniculus adiposus
- Rest EF without alterations

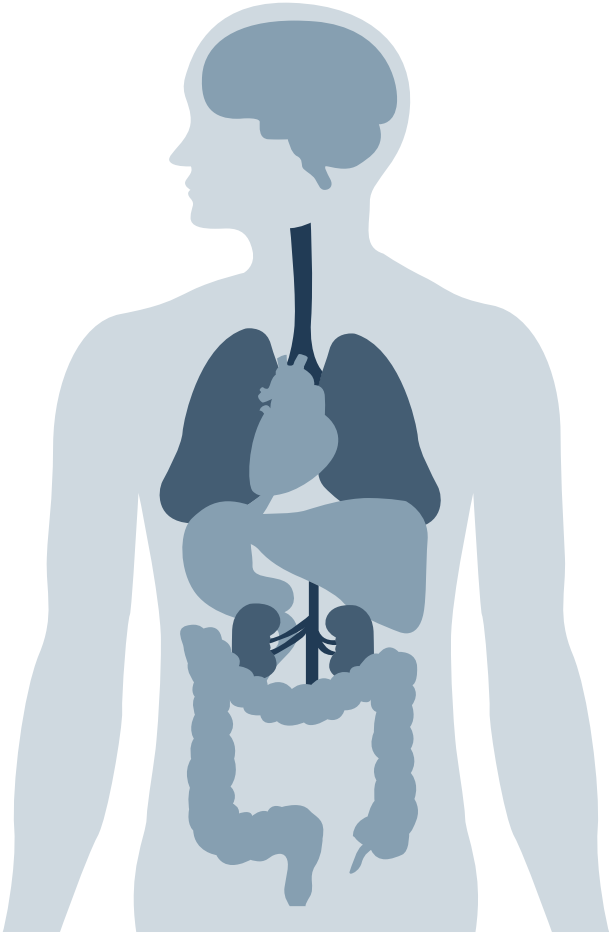

Neurological examination

Mental function

- **State**
  - Alert
  - Cooperates
  - Orientated
- **Language:** expresses language, understands orders, repeats and nominates; has dysarthria
- **Memory:** no alterations
- **Calculation:** no alterations
- **Abstract thought:** no alterations

Neurological examination

I. Not examined

II.

- VA: deferred
- Fundus difficult to assess, normal color vision
- Visual fields without alterations

III, IV y VI:

- Right eye:
  - Primary gaze with exotropia
  - ADD limitation
- Left eye
  - Central primary gaze
  - Fixed horizontal and vertical motion preserved
  - Horizontal RE nystagmus to the ABD
- Symmetric pupils 2 mm
- Consensual and photomotor reflex without alterations

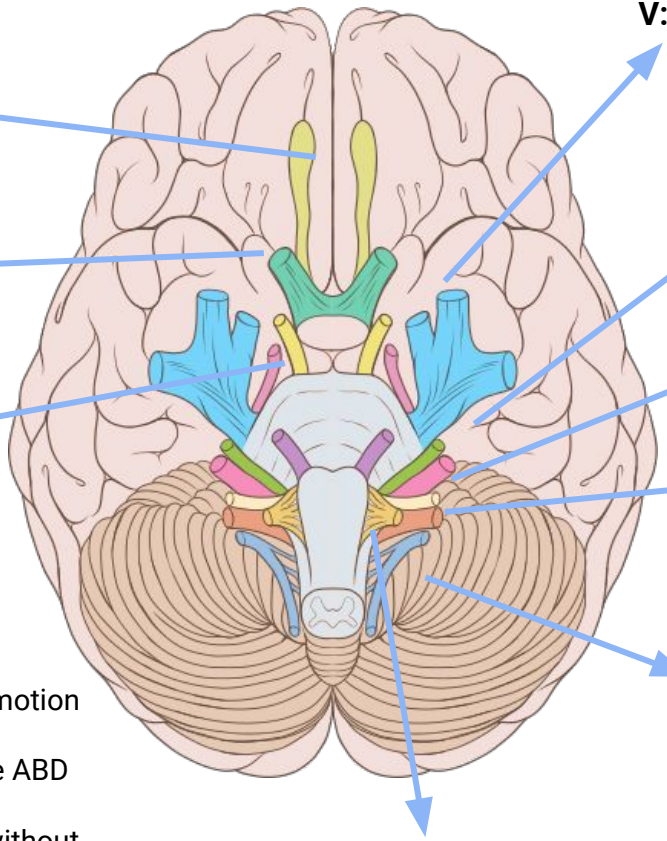

V:Hypoaesthesia right side of the face

VII. Facial asymmetry with effacement of the right nasolabial fold, preserved frontal movement

VIII. No alterations

IX,X. No alterations

XI. Asymmetric, does not elevate right shoulder

XII. No alterations

Neurological examination

Motor System

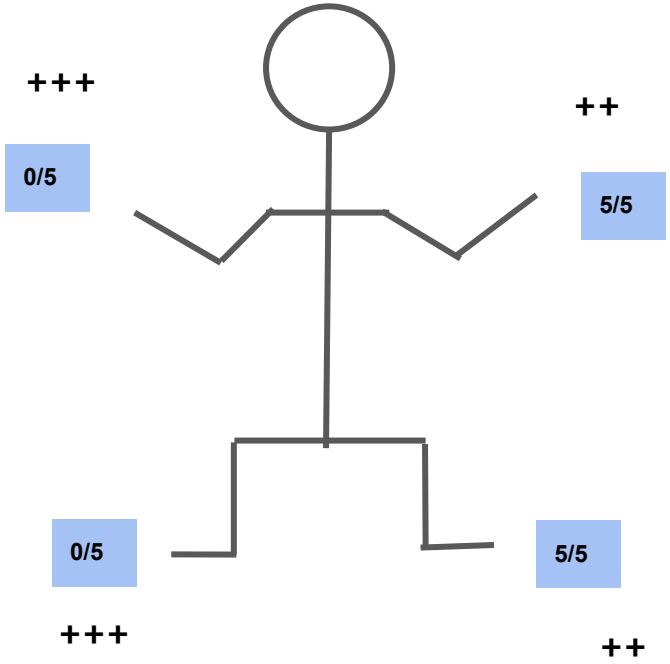

- **Trophism:** no alterations
- **Tone:** no alterations
- **Pathological reflexes:** right extensor plantar response present
- **Atavistic reflexes:** absent

Neurological examination

Sensitivity

- **Hypoesthesia of the right side of the body**
- **Temperature:** not examined
- **Pain:** not examined
- **Superficial touch**
  - Left hemibody: intact
  - Right hemibody: reduced
- **Vibration**
  - Left hemibody: intact
  - Right hemibody: reduced
- **Bathyesthesia:** not examined
- **Romberg:** not examined because patient could not stand

Neurological examination

Cerebellum, gait and abnormal movements

- **Gait:** not assessable because patient cannot stand
- **Abnormal movements:** not displayed during examination
- **Cerebellum:**
  - Without dysmetria or dysdiadochokinesia in the left hemibody
  - Non-assessable right due to plegia

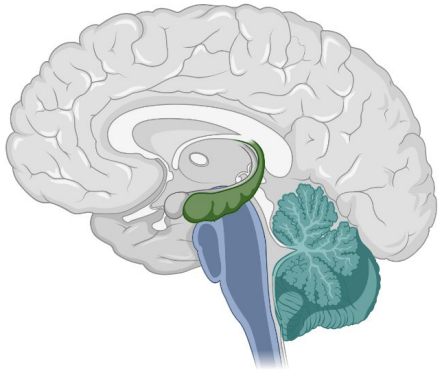

Neurological examination

Meningeal signs

- Neck stiffness, Kernig, and Brudzinski → Absent

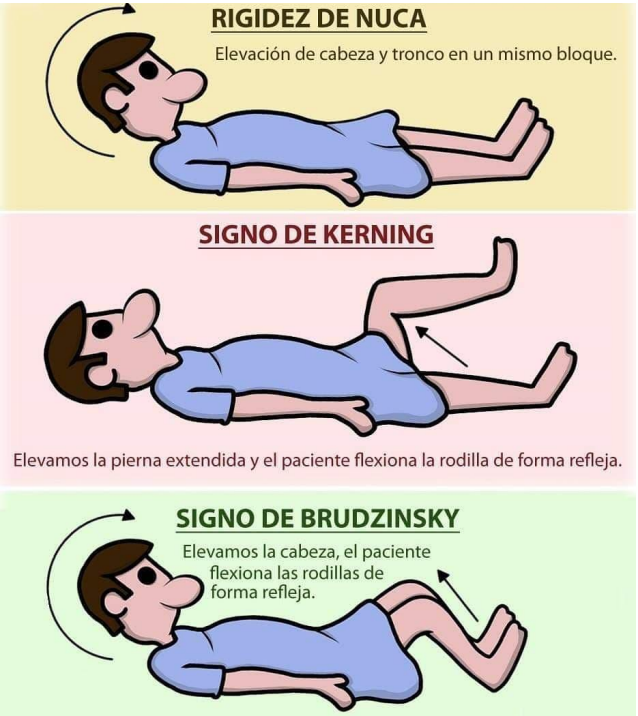

NIHSS scale

➔ Impairment caused by stroke

Evaluación	Respuesta	Puntaje	Evaluación	Respuesta	Puntaje
1a. Nivel de conciencia	Alerta Somnoliento Estuporoso Coma	0 1 2 3	**6a. Motor miembro inferior**	Sin caída Caída No resiste la gravedad No ofrece resistencia No movimiento Amputación/artrodes.	0 1 2 3 4 NE
1b. Preguntas (mes, edad)	Ambas correctas 1 rpta. Correcta Ambas incorrectas	0 1 2	**6b. Motor miembro inferior**	Sin caída Caída No resiste la gravedad No ofrece resistencia No movimiento Amputación/artrodes.	0 1 2 3 4 NE
1c. Ordenes (abra y cierre los ojos, haga puño y suelte)	Obedece ambas Obedece 1 orden No obedece ninguna	0 1 2	**7. Ataxia de miembros**	Ausente Presente en 1 miembro Presente en 2 miembro Amputación/artrodesis	0 1 2 NE
2. Mirada (sigue dedo/ examinador)	Normal Parálisis parcial Desviación forzada	0 1 2	**8. Sensibilidad**	Normal Hipoestesia leve-mod Hipoestesia mod-sev	0 1 2
3. Visión (presente estí-mulos/amena-zas visuales a 4 campos	Visión normal Hemianopsia parc Hemianop. Compl. Hemianop. Bilat.	0 1 2 3	**9. Lenguaje**	Normal Afasia leve Afasia moderada Afasia global	0 1 2 3
4. Parálisis facial	Normal Leve Moderada Severa	0 1 2 3	**10. Disartria**	Normal Disartria leve – mod. Disartria mod – severa Paciente intubado	0 1 2 NE
5a. Motor miembro superior	Sin caída Caída No resiste gravedad No ofrece resistencia No movimiento Amputación/artrodes.	0 1 2 3 4 NT	**11. Extención e inanten-ción evaluar desatención / estimulación doble simultán**	No desatención Desatención parcial Desatención completa	0 1 2
5b. Motor miembro superior	Sin caída Caída No resiste gravedad No ofrece resistencia No movimiento Amputación/artrodes.	0 1 2 3 4 NT		Total	**14**

14 points
→ Moderate Déficit

- <4: Mild deficit
- 5-15: Moderate deficit
- 16-20: moderate/severe deficit
- >20 Severe deficiency

Diagnosis

Sindromatic:

- Right dense facio-brachio-crural pyramidal syndrome
- One and a half syndrome
- Right exteroceptive sensory syndrome

Topographic

- Intraaxial
- Central
- Infratentorial
- Pontine

Etiological

- Left pontine infarction
- Pontine arteries branches of the basilar
- Atherogenic?

Laboratory and cabinet studies

Parameter	Result
Glucose	85 mg/dl
Creatinine	**3.3 mg/dL**
Urea	85 mg/dL

BH, coagulation times, rest
QS: NO alterations

Laboratory and cabinet studies

Type of study

- DWI

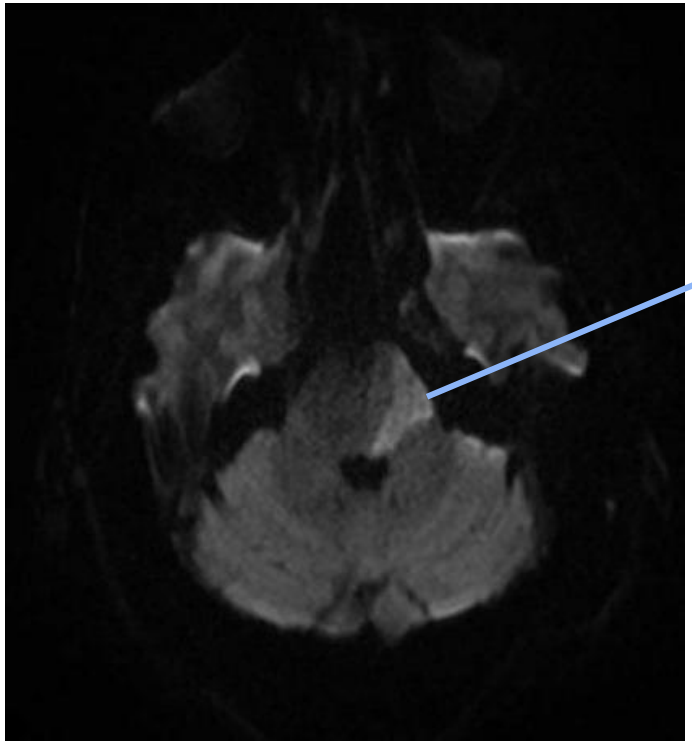

Hyperintensity at the left lateral pontine level and partially left middle cerebellar peduncle

Laboratory and cabinet studies

Type of study

- FLAIR

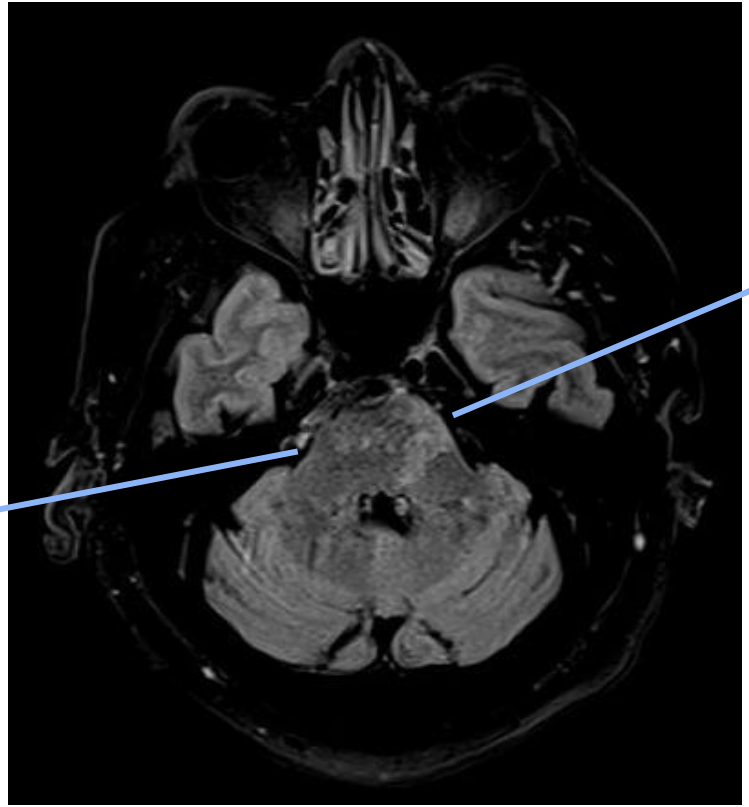

Left pontine hyperintensity (recent stroke)

Right pontine punctal hyperintensity (old lacunar strokes)

Clinico-topographic integration

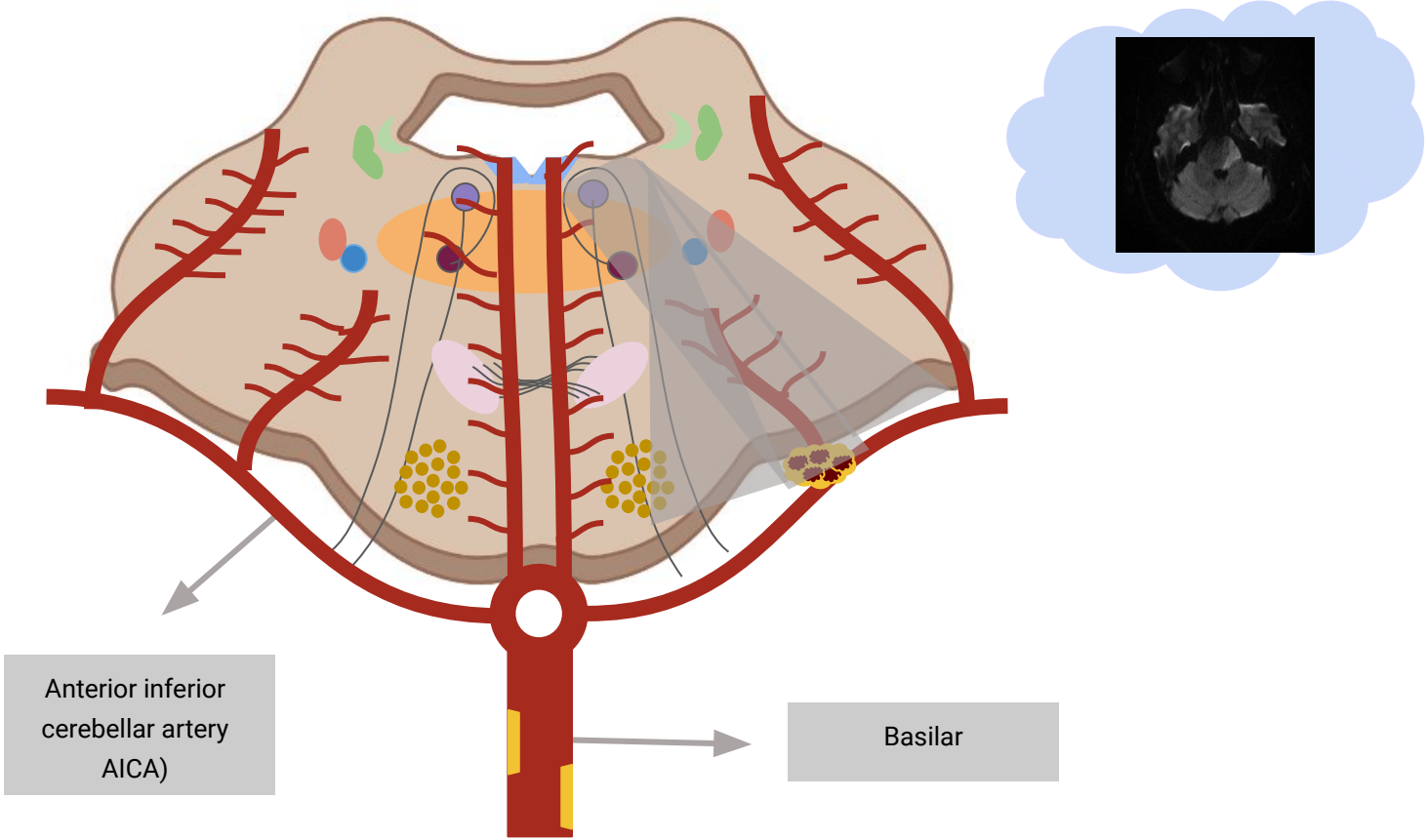

Clinico-topographic integration

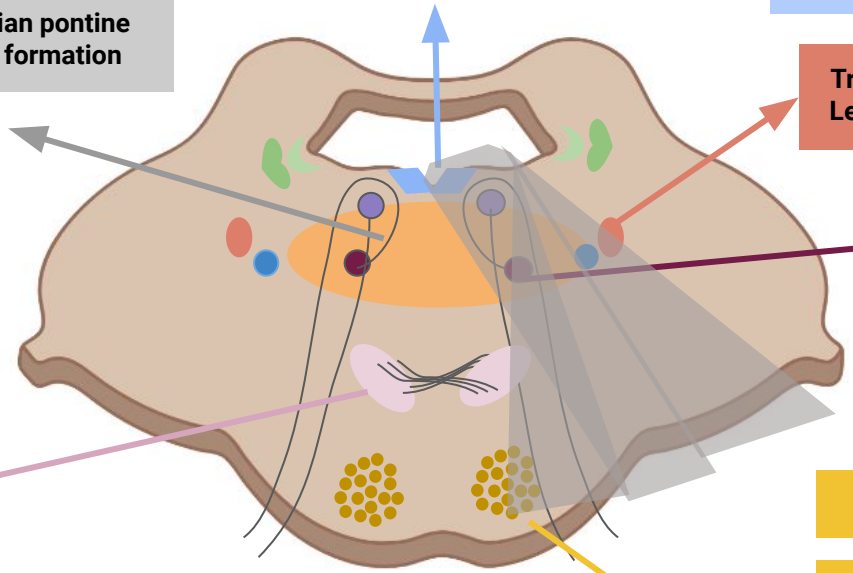

Medial longitudinal fasciculus

Contralateral internuclear ophthalmoplegia

ipsilateral gaze palsy

Paramedian pontine reticular formation

Trigeminal Lemniscus

Contralateral hemihypoesthesia

Corticofacial fasciculus

Contralateral central facial palsy

Medial lemniscus

Loss of superficial touch and contralateral vibration (Sensory Ataxia)

Corticospinal Tract

Sx pyramidal

- Contralateral hemiparesis
- hyperreflexia
- Babinski present

Cerebral Vascular Disease

Cerebral vascular disease (CVD)

- Cerebral vascular disease (CVD) is a clinical syndrome characterized by the rapid development of focal neurological signs, which persist for more than 24 h, with no apparent cause other than vascular origin.
- Most common cause of disability in adults
- 5th death in our country.

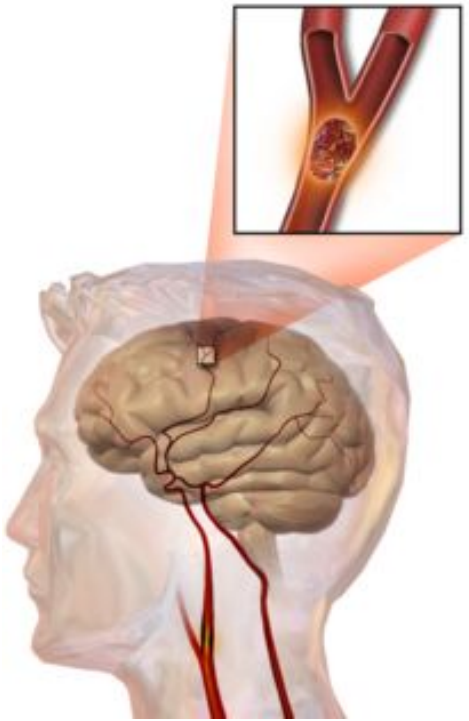

Arauz A, Ruíz-Franco A. Enfermedad vascular cerebral [Internet]. Medigraphic.com. [citado el 18 de octubre de 2021]. Disponible en: https://www.medigraphic.com/pdfs/facmed/un-2012/un123c.pdf
Instituto Nacional de Neurología y Neurocirugía [Internet]. Gob.mx. [cited 2021 Oct 18]. Available from: http://www.innn.salud.gob.mx/interna/medica/padecimientos/evascularcerebral.html

CVD classification

- **CVD**
  - Ischemic (70-80%)
    - TIA (20%)
    - Cerebral stroke (80%)
  - Hemorrhagic (20-30%)
    - Intracerebral hemorrhage (10-15%)
    - Subarachnoid hemorrhage (5-7%)

Cerebral infarction (80%) → Obstruction of blood flow → Classification by production mechanism: TOAST

- Atherosclerosis of large vessels
- Cardioembolism
- Cerebral small vessel disease
- Other causes
- Cryptogenic

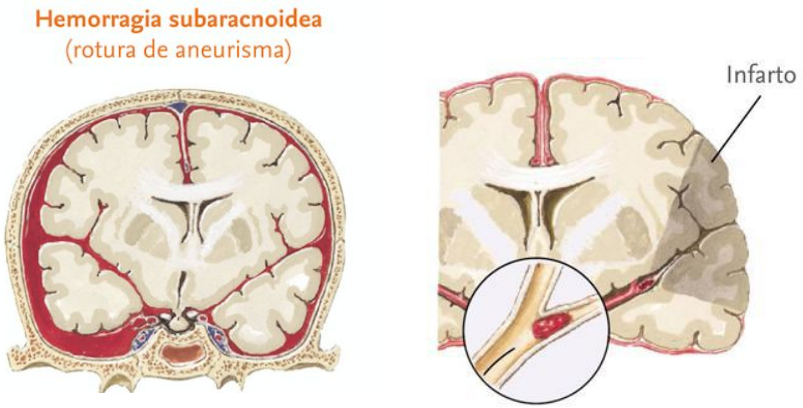

Arauz A, Ruíz-Franco A. Enfermedad vascular cerebral [Internet]. Medigraphic.com. [citado el 18 de octubre de 2021]. Disponible en: https://www.medigraphic.com/pdfs/facmed/un-2012/un123c.pdf
Instituto Nacional de Neurología y Neurocirugía [Internet]. Gob.mx. [cited 2021 Oct 18]. Available from: http://www.innn.salud.gob.mx/interna/medica/padecimientos/evascularcerebral.html

Risk factors

Modifiable Factors

- Hypertension
- smoking
- Alcoholism
- Diet
- Obesity
- Dyslipidemias
- Physical activity
- Cardiovascular diseases: AF

NON-modifiable factors

- Age: significant increase after 55 years
- Race/Ethnicity: Black, Latino
- Male gender

Boehme AK, Esenwa C, Elkind MSV. Stroke risk factors, genetics, and prevention. Circ Res. 2017;120(3):472–95. https://www.ahajournals.org/doi/pdf/10.1161/CIRCRESAHA.116.308398#:~:text=Risk%20factors%20for%20stroke%20can,commonly%20reported%20modifiable%20risk%20factors.

Pontine strokes

Brainstem ischemic strokes are only 10% of cerebral ischemic strokes

- Ventral
  - Anteromedial
  - Anterolateral
- Dorsolateral
  - Rostral
  - Caudal

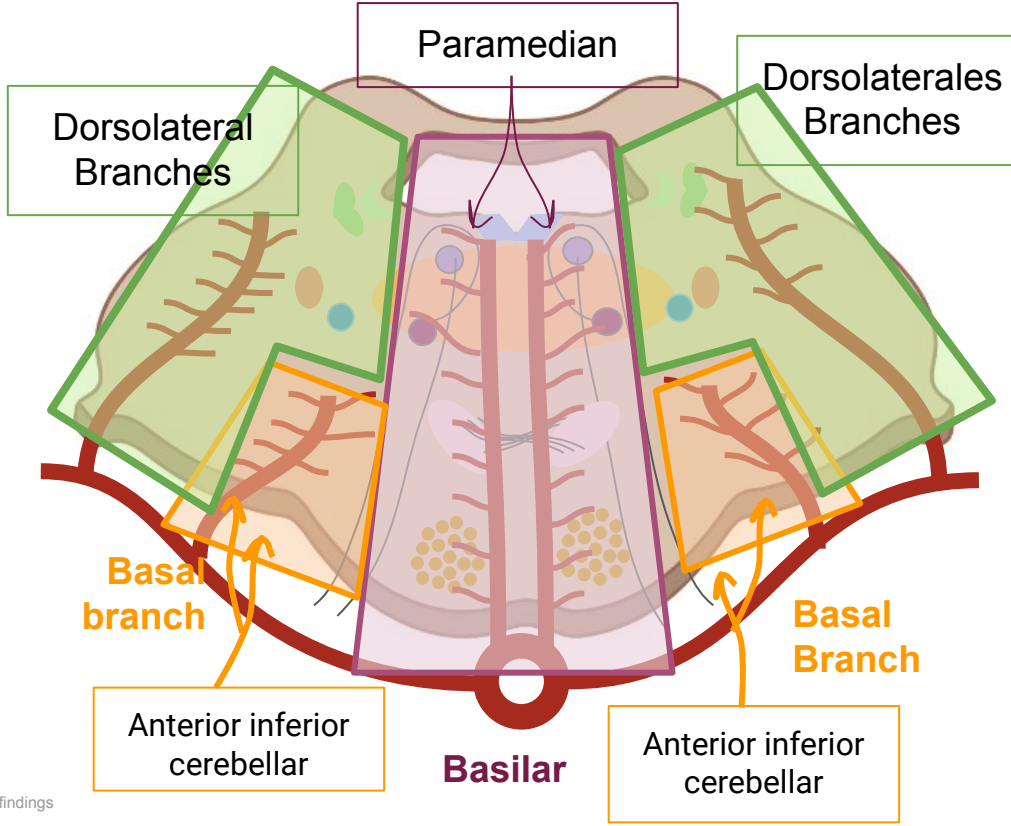

Ortiz de Mendivil A, Alcalá-Galiano A, Ochoa M, Salvador E, Millán JM. Brainstem stroke: anatomy, clinical and radiological findings
Gowda SN, De Jesus O. Brainstem Infarction. En: Stat Pearls. Treasure Island (FL): StatPearls Publishing; 2021.

One and a half syndrome

MLF injury + FRPP injury
MLF injury + VI nuclei injury

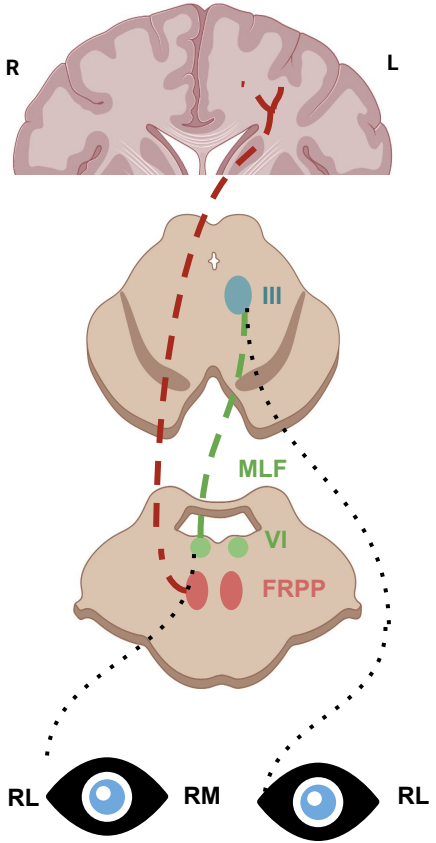

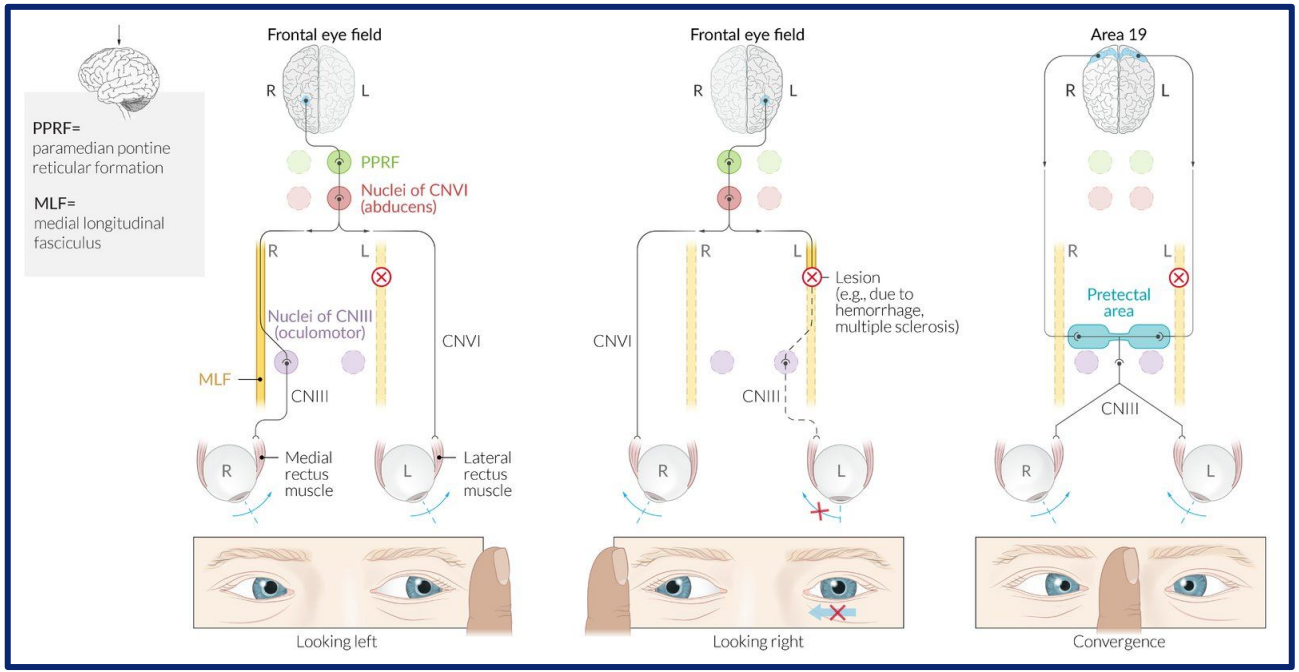

Westover, M., Decroos, E., & Bianchi, M. (2017). Neurología de Bolsillo (pp. 594-599). Philadelphia: Wolters Kluwer.

References:

- Arauz A, Ruíz-Franco A. Enfermedad vascular cerebral [Internet]. Medigraphic.com. [citado el 18 de octubre de 2021]. Disponible en: https://www.medigraphic.com/pdfs/facmed/un-2012/un123c.pdf
- Instituto Nacional de Neurología y Neurocirugía [Internet]. Gob.mx. [cited 2021 Oct 18]. Available from: http://www.innn.salud.gob.mx/interna/medica/padecimientos/evascularcerebral.html
- Ortiz de Mendivil A, Alcalá-Galiano A, Ochoa M, Salvador E, Millán JM. Brainstem stroke: anatomy, clinical and radiological findings
- Gowda SN, De Jesus O. Brainstem Infarction. En: Stat Pearls. Treasure Island (FL): StatPearls Publishing; 2021.
- Westover, M., Decroos, E., & Bianchi, M. (2017). Neurología de Bolsillo (pp. 594-599). Philadelphia: Wolters Kluwer.
- Kleindorfer DO, Towfighi A, Chaturvedi S, et al. 2021 Guideline for the Prevention of Stroke in Patients With Stroke and Transient Ischemic Attack: A Guideline From the American Heart Association/American Stroke Association. Stroke .2021. doi: 10.1161/str.0000000000000375
- Mandell J. Core Radiology. Cambridge University Press; 2013
- Powers WJ, Rabinstein AA, Ackerson T, et al. Guidelines for the Early Management of Patients With Acute Ischemic Stroke: 2019 Update to the 2018 Guidelines for the Early Management of Acute Ischemic Stroke: A Guideline for Healthcare Professionals From the American Heart Association/American Stroke Association. Stroke 2019; 50:e344.