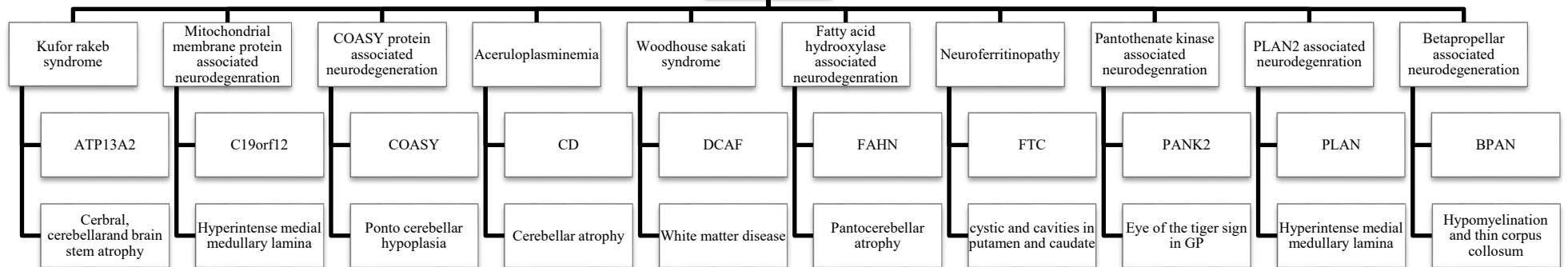


Neurological  
manifestation of  
excess iron

NBIA



Wajih Ansari  
Medical Graduate  
Baqai medical university

NBIA-Neurodegeneration with brain  
iron accumulation  
GP-globus pallidus