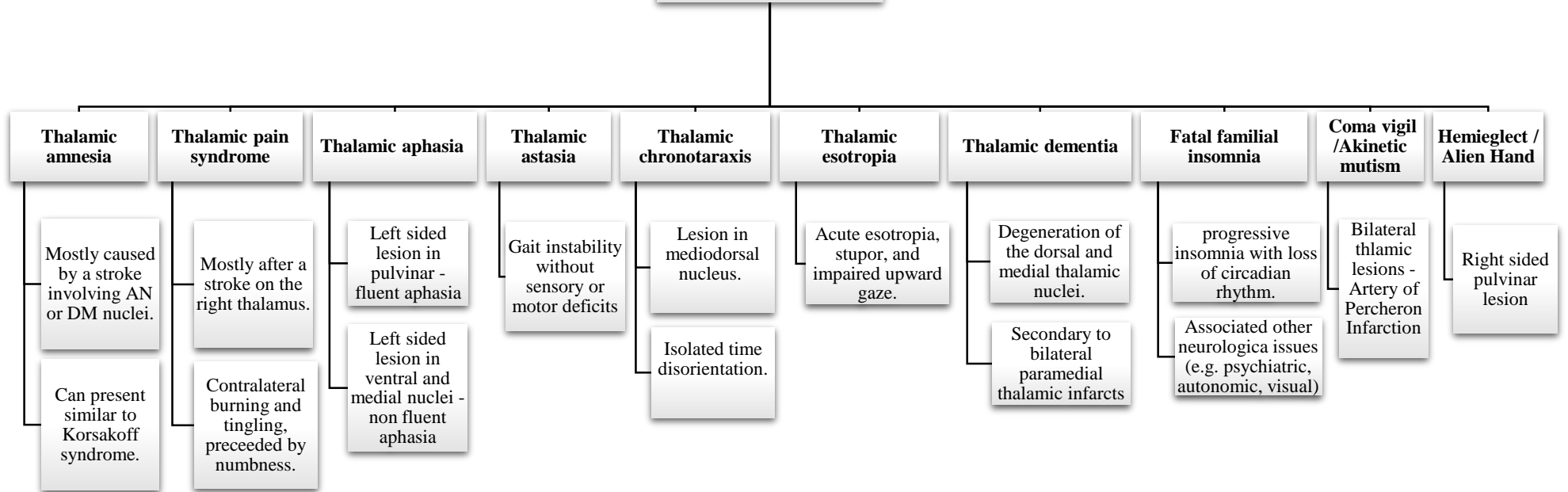


## Thalamic syndromes



AN – Anterior nucleus  
DM – Dorsomedial nucleus

Ibrahim Alkhodair – July 2021